

REVIEW



Current concepts in midface fracture management

AQ1

Alf L. NASTRI and Ben GURNEY

AQ4

Purpose of review

Management of midface trauma is complex and challenging and requires a clear understanding of the facial buttress system, subunit anatomy and inter-relationships. Too often clinicians attempt surgical repair without adequate knowledge of the common complications associated with poor reduction and improper sequencing of fracture repair. This review outlines a working approach to the identification and management of such injuries, and the definitive management of common injury patterns.

Recent findings

Midface trauma, with or without life-threatening and sight-threatening complications, may arise following isolated injury, or be associated with significant injuries elsewhere. Assessment needs to be both systematic and repeated, with the establishment of clearly stated priorities in overall care.

Summary

Accurate and precise relocation of bony subunits and resuspension of soft tissues is vital in achieving acceptable functional and aesthetic outcomes.

Keywords

facial buttress, Le Fort, midface fracture, zygomatico-maxillary complex (ZMC)

INTRODUCTION

The aim of this article is to cover some relevant and contemporary issues with regard to midface fracture management. Midface injuries are often associated with high kinetic energy transfer to multiple subunits of the facial skeleton; they are complex in nature and can present surgeons with serious acute issues requiring emergency management. These are mainly because of the proximity of the airway and the rich vasculature of the skull base and midface region. Furthermore, concomitant injuries to the head and brain, C-spine and orbital region can complicate the management of these patients, requiring a systematic multidisciplinary and often customized approach. Rather than offering a complete discussion of the complexities of midface injuries within the context of polytrauma and panfacial injuries, we aim to focus our approach on some typical midface presentations, with emphasis on specific clinical cases, to outline some of the important concepts to consider. We will also identify current and future developments in technology, which may aid surgeons in improving outcomes for patients treated for this group of injuries.

ACUTE MANAGEMENT

Our focus is on definitive surgical management of midface fractures rather than acute stabilization of

the patient, but this stage of management is critical. ATLS principles apply, although strict adherence to protocols is not always appropriate when facial trauma co-exists. An excellent reference for ATLS principles with regard to facial trauma is by Perry, published in the *International Journal of Oral and Maxillofacial Surgery*, 2008 [1–4]. With regard to midface injuries in particular, the rich blood supply and capacity for swelling means that both airway and circulation can be rapidly compromised and rapid manoeuvres to stabilize these elements should be applied as part of the primary survey. Definitive management can normally be delayed until the patient is more physiologically stable and soft tissue swelling has reduced.

CONTEMPORARY CLASSIFICATION CONCEPTS

Much of the literature and teaching regarding midface fracture assessment references the well-known

Maxillofacial Surgery, Royal Melbourne Hospital, Melbourne, Australia
Correspondence to Alf L. NASTRI, MBBS, MSc, FRACDS (OMS), Associate Professor, Head of Department, Maxillofacial Surgery, Royal Melbourne Hospital, Level 5, 766 Elizabeth Street, Melbourne 3000, Australia. Tel: +61 39342 8892; e-mail: anastri@me.com

Curr Opin Otolaryngol Head Neck Surg 2016, 24:000–000
DOI:10.1097/MOO.0000000000000267

Maxillofacial surgery

KEY POINTS

- Knowledge of the facial skeletal buttress system is important.
- 3D imaging modalities allow precision planning.
- Selection of midface approaches based on fracture pattern.
- Midface fractures require a customized treatment plan.

Le Fort classification [5], which although reproducible, in reality is often not representative of typical fracture configurations in their entirety. Midface fracture patterns are rarely symmetrical, often have a combination of the recognized Le Fort levels, are comminuted, and exist alongside fractures of the naso-ethmoidal and frontal region, zygomatico-orbital complex and mandible. Furthermore, as more modern computed tomography (CT) techniques provide higher definition diagnostic images with 3D formatting, finer fracture patterns can be visible which only serves to complicate classification [6,7]. More modern midface staging systems exist [8,9,10^{*},11], but the chief aim for any classification framework is to enable the facial surgeon to understand which fractures are severe enough to destabilize the functional and cosmetic components of the face, therefore determining the extent of operative reduction and fixation required.

ANATOMICAL CONCEPTS: BUTTRESSES, SUBUNITS AND SUTURAL RELATIONSHIPS

Anatomically relevant and surgically accessible craniofacial buttresses guide the reduction and fixation of the skeleton and have been well documented. The three-paired transverse and vertical midface buttresses (the fourth pair includes the mandible) provide areas of increased bone thickness that support the functional units of the face: the airway, the dental occlusion, the muscle attachments and the eyes. These buttresses must directly or indirectly interface with the cranial base to offer facial support, and they therefore represent the fundamental reference points for fixation when fractures have occurred.

It is often useful to consider which buttresses are involved with each configuration of midface fracture. Figure 1 shows the standard Le Fort classification with respect to the facial buttresses.

A Le Fort I fracture involves two vertical buttresses – the inferior medial maxillary (at the pyriform aperture) and inferior lateral maxillary buttresses to give a potentially mobile maxilla.

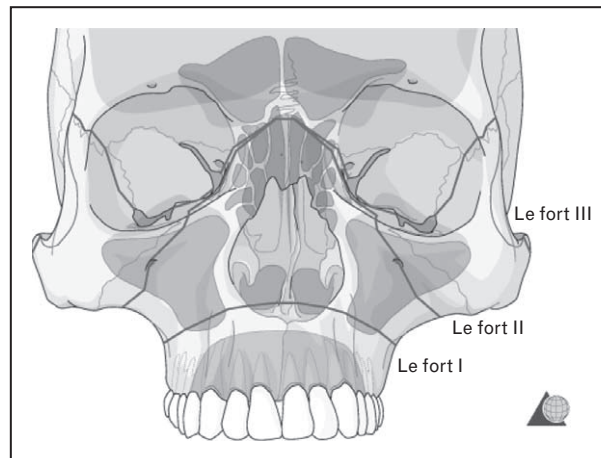


FIGURE 1. Classic Le Fort fracture patterns with buttresses superimposed. Reproduced with permission from AOCMF.

A Le Fort II fracture involves the upper transverse maxillary buttress (inferior orbital rim) and lateral maxillary buttress, orbital floor and nasofrontal junction.

A Le Fort III fracture involves separation of the midface at the zygomatic arch, along with fronto-zygomatic and speno-zygomatic sutures, orbital floor and nasofrontal junction.

A further consideration is the AOCMF description of facial subunits with reference to the midface, which are illustrated in Fig. 2. The midface units are the elements of the facial skeleton below the fronto-zygomatic, fronto-maxillary and fronto-nasal sutures, and essentially split the midface into central and lateral portions.

This description has led to a more contemporary classification: the Level 3 AOCMF classification, demonstrated in Fig. 3. This is tailored to delineate the Le Fort fracture patterns with the help of three virtual horizontal partitions, stacked one upon the other along the vertical nasomaxillary buttresses of the central midface.

Alongside buttresses and facial subunits, the relevant sutural relationships should be considered – in particular the nasofrontal, zygomatico-frontal and zygomatico-sphenoid sutures. These transitional bony junctions can become dissociated or indeed impacted, and represent important reference reduction and fixation points.

An important concept is that for a maxillary fracture to be considered a 'Le Fort' fracture, disruption of the posterior maxilla from the pterygoid plates should be present, as this represents separation from the cranial base, resulting in a more unstable injury. The palate must be thought of as a separate entity, and can fracture or split in 8% of cases [11]. A palatal fracture can cause widening of

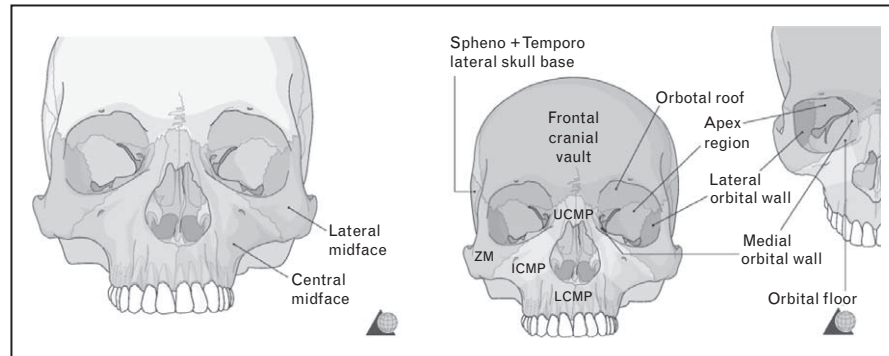


FIGURE 2. Facial skeletal subunits. ICMP, intermediate central midface partition; LCMP, lower central midface partition; UCMP, upper central midface partition. Reproduced with permission from AOCMF.

the maxillary arch, as seen in Fig. 4, and so must be evaluated correctly.

CONCOMITANT INJURIES

Owing to the high forces required to fracture the midfacial skeleton, concomitant panfacial type fracture patterns often co-exist, and this again requires a customized approach.

MANDIBLE

Simultaneous mandibular fractures require further consideration of the maxillo-mandibular complex with regard to restoring the dental occlusion and facial height and width. Occlusal restoration with an intact mandible is clearly easier but requires an understanding of condylar positioning. If the condylar heads are not placed correctly with a reduced and passive maxillary dental component, then an open bite malocclusion will ensue upon removal of

the intermaxillary fixation. This concept is illustrated in Fig. 5.

ORBITAL

In the first instance, a high percentage of midfacial fractures have associated ocular and orbital injuries [12], which must be considered with every midface injury and fracture repair. During midface fixation itself, a decision is required whether or not to explore the orbit and reconstruct the internal walls. Surgical access for orbital reconstruction can be shared with access required to fix the periorbital framework. It is also important to consider secondary effects of manipulation of the midfacial bones on the orbit and its contents by evaluating extension of fracture lines. There is potential for significant volume change along with entrapment of periorbita. A postmanipulation forced duction test is therefore necessary if the orbit is not going to be formally explored.

NASO-ORBITAL-ETHMOIDAL/FRONTAL

The naso-orbital-ethmoidal region represents the medial vertical buttress to the face and can be

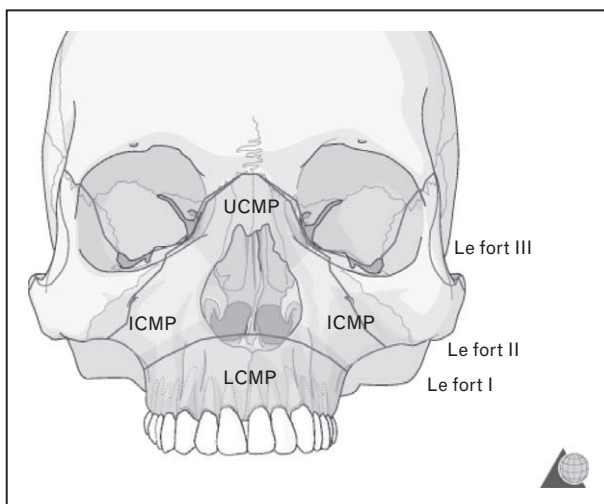


FIGURE 3. ICMP, intermediate central midface partition; LCMP, lower central midface partition; UCMP, upper central midface partition. Reproduced with permission from AOCMF.

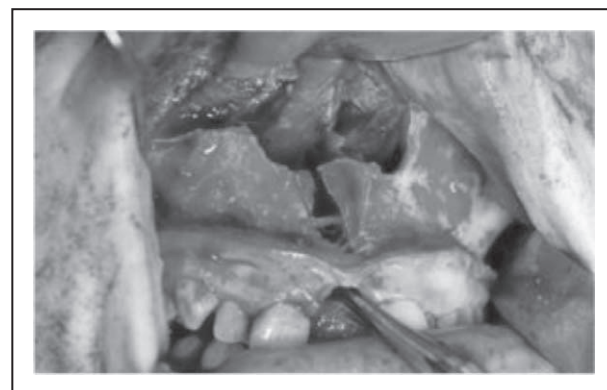


FIGURE 4. Le Fort I injury with midline palatal fracture.

Maxillofacial surgery

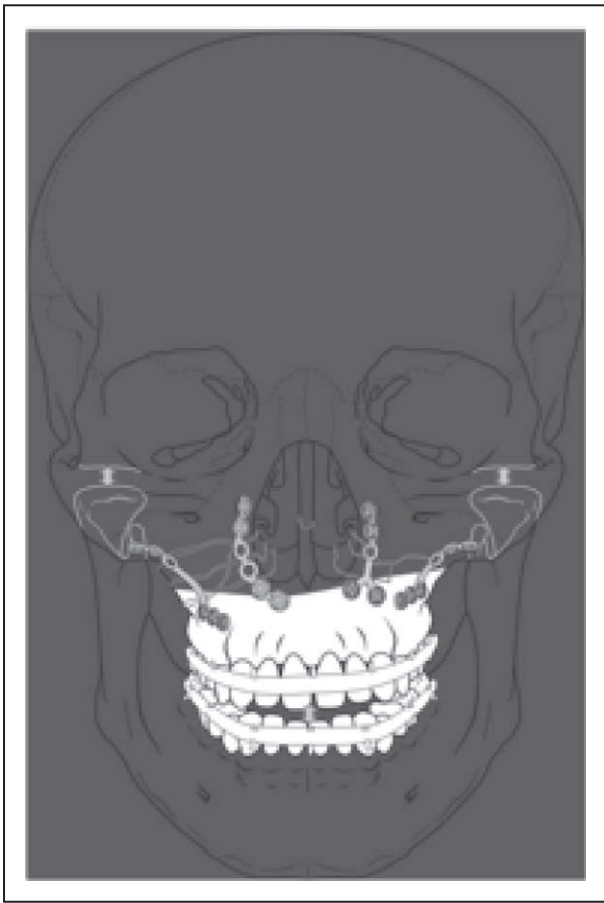


FIGURE 5. Condylar positioning and its relationship to the occlusion. Reproduced with permission from AOCMF.

considered a separate entity. This region requires localized high kinetic energy transfer to fracture and does so as part of the 'crumple zone' effect, leading to various functional and aesthetic deformities. Telcanthus, epiphora, nasofrontal duct damage and cribriform plate injury can all be associated with these fractures. Particular attention should be paid to the attachments of the medial canthi, and whether the central tendon bearing bone segments require repositioning. If the area is comminuted, then transnasal wiring is required.

Midface fractures may extend into orbital roofs, frontal sinus walls, ethmoidal and sphenoidal bones if the traumatic impact is of sufficient force, and the significant potential of a dural injury, skull base fracture, intracranial haemorrhage or a cervical spine fracture should be borne in mind.

MANAGEMENT CONCEPTS

Bone

Once an accurate diagnosis has been made, and priority of treatment has been ascertained, early

functional and anatomical reconstruction should be achieved. Appropriate exposure of the vertical and horizontal buttresses of the midface enables disimpaction, reduction with three-dimensional control, followed by rigid fixation of the fractured segments. Primary bone grafting can be considered to restore skeletal form in which a bony buttress is severely comminuted or defective, in order to achieve adequate bony continuity, facial contour and prevent soft tissue collapse. Gaps of over 5 mm would generally require bone grafting with donor options including iliac crest, cranial or mandibular bone. Common areas that may require bone grafting include the frontal bone, nasal dorsum, orbital floor, medial orbital wall and zygomaticomaxillary buttress [13].

Access and exposure

Minimal surgical access should be, in the main, decided preoperatively and achieved efficiently at the start of the case to maximize exposure of the fractured areas, and allow further time for achieving accurate reduction and fixation.

Access incisions are chosen based on the portions of the midface requiring visualization and fixation. A coronal incision is essential for comminuted zygomatic arch fractures or where facial width needs to be assessed. It also allows excellent access to the frontal bone, superior orbital rims, fronto-zygomatic suture and nasofrontal suture, and if necessary naso-ethmoidal region and medial canthal ligament attachments. Orbital work can be performed through either a transcutaneous lower lid incision or a transconjunctival approach. It is the author's view that rim fixation and orbital floor access is more readily achieved through a transcutaneous subtarsal incision, but again a customized approach is required. If the orbital floor defect is limited, or there are no lower eyelid skin creases, then a transconjunctival incision with or without lateral canthotomy/transcaruncular extension can be a better option. The fronto-zygomatic suture can be effectively approached through upper blepharoplasty incisions, whilst the remainder of the maxillary zygomatic region is easily accessed through an upper vestibular intraoral approach.

Fixation hardware

Several systems are now available for midface fixation offering a good choice of plates and screws and preference is generally personal. It is important to consider the profile of the plates used at different anatomical locations with regard to thickness of

overlying soft tissue versus strength and rigidity required from the plate. Orbital rims suit a lower profile plate whereas the zygomatic buttress and maxilla can support higher profile plates without risk of being visible or palpable externally. The craniofacial plate industry in more recent years has managed to develop thinner implants with equal strength to facilitate such low profile fixation. Resorbable systems have been studied and are used in some centres [14], but the authors do not support their use as routine in adult trauma.

Soft tissue management

The final essential element is resuspension of soft tissues, and this represents a stage that has been overlooked in the past, leading to substandard results. The aim here is to fix the periosteum to the bone in a superior position to prevent inferior reattachment after trauma surgery. The areas of importance are the malar eminence and infraorbital rim, temporal fascia over the zygomatic arch, medial and lateral canthi and mentalis muscle [11] (Fig. 6).

As restoration of the premorbid dental occlusion is mandatory, nasotracheal intubation is required for fixation under general anaesthesia. If this is not feasible, submental intubation can be considered or a tracheostomy.

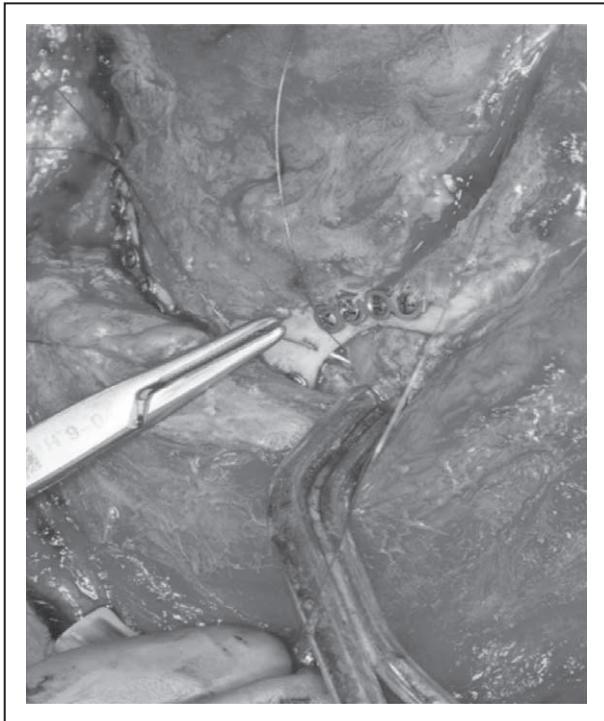

FIGURE 6. Nylon suture placed through lateral orbital rim for resuspension of soft tissue.

SUMMARY

A customized approach should be applied to all patients with a midface fracture. Contemporary analysis and staging of the injury is required with relation to the aforementioned anatomical concepts (buttressing, subunits, sutural relationships and soft tissue volume change) to aid sequencing of surgical management. Analysis must be three-dimensional for the facial skeleton, with overlying soft tissue resuspension representing the fourth dimension. This can then guide choice of surgical access. The three case examples (Figs 7–9) that follow demonstrate the key management concepts discussed.

Case examples

Case 1: Comminuted bilateral zygomatico-maxillary complex fractures (Le Fort III) resulting in reduced malar projection, particularly on the right, with complete Le Fort I level fracture resulting in maxillary mobility and malocclusion, and additional fronto-nasal dysjunction. AQ6

Approaches: Coronal, bilateral subtarsal, upper vestibular incisions. This patient also required radiologically guided ligation of his right sphenopalatine artery as a result of posttraumatic haemorrhage 1 week prior to surgery.

Fixation: Horizontal and vertical facial buttresses plated as seen. Orbital volume, malar projection and facial width were restored. The internal orbital walls were comminuted but maintained, and thus exploration was not required (Fig. 7).

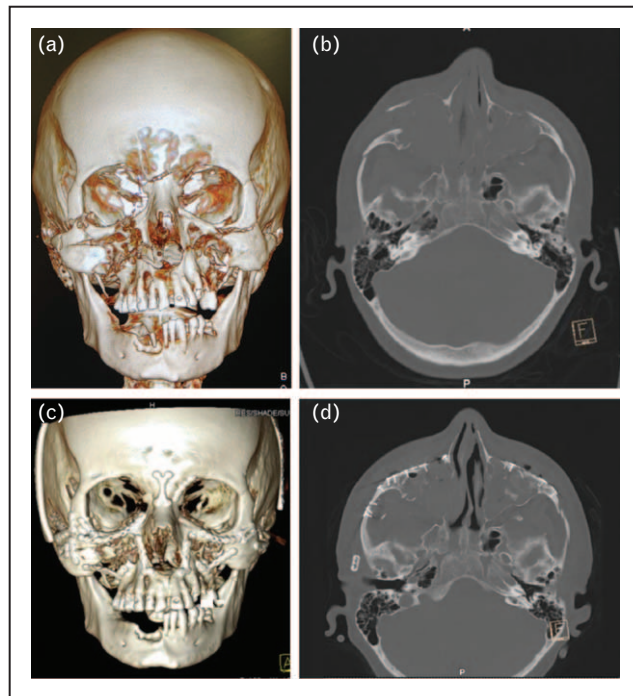


FIGURE 7. (a–d) Comminuted bilateral zygomatico-maxillary complex fractures. AQ9

Maxillofacial surgery

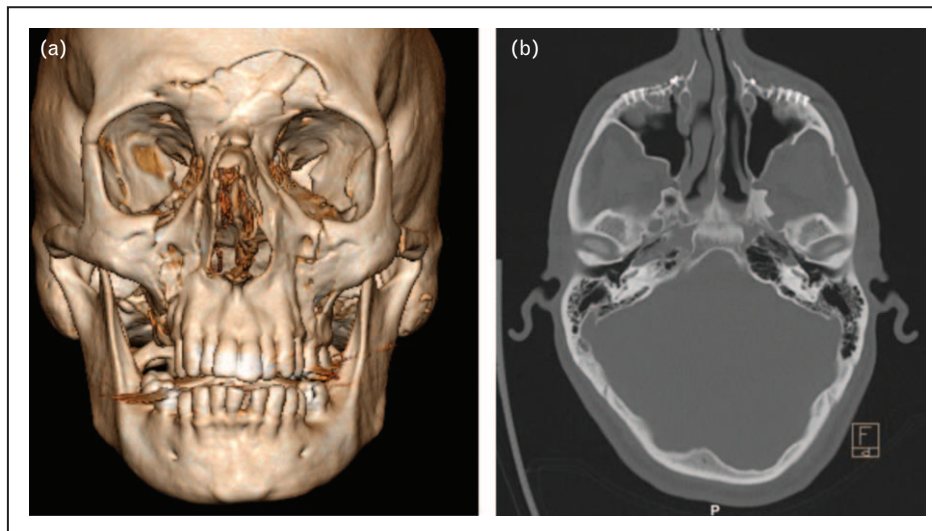


FIGURE 8. (a) Horizontal and (b) vertical facial buttresses.

Case 2: Bilateral Le Fort II fractures with mobile maxilla and malocclusion; minimally depressed comminuted anterior table frontal sinus fracture; fractured nasal bones

Approaches: Bilateral upper vestibular and bilateral subtarsal incisions were made and there was a closed manipulation of the nasal bones. The frontal sinus fracture was managed non-operatively.

Fixation: Midface projection and width was anatomically restored via this minimal access approach; fixation is seen at the Le Fort I level and the inferior orbital rims (Fig. 8).

Case 3: Right zygomatico-maxillary complex fracture with depression and widening and naso-maxillary extension, and bilateral pterygoid plate dysjunction with potentially mobile maxilla.

Approaches: Bilateral upper vestibular, right upper blepharoplasty.

Fixation: Right zygomatico-frontal suture, zygomatico-maxillary buttress and left piriform rim. Occlusion was re-established with intraoperative MMF (Fig. 9).

CURRENT AND FUTURE DEVELOPMENTS

There now exist a number of new areas of technological development, which may aid the facial surgeon in the management of midface fractures into the future. Specifically, computer-assisted surgery may take the form of presurgical analysis and planning and intraoperative navigation and assessment. Additionally endoscopically assisted surgery has received increased interest in recent years, but its use in the trauma setting remains limited.

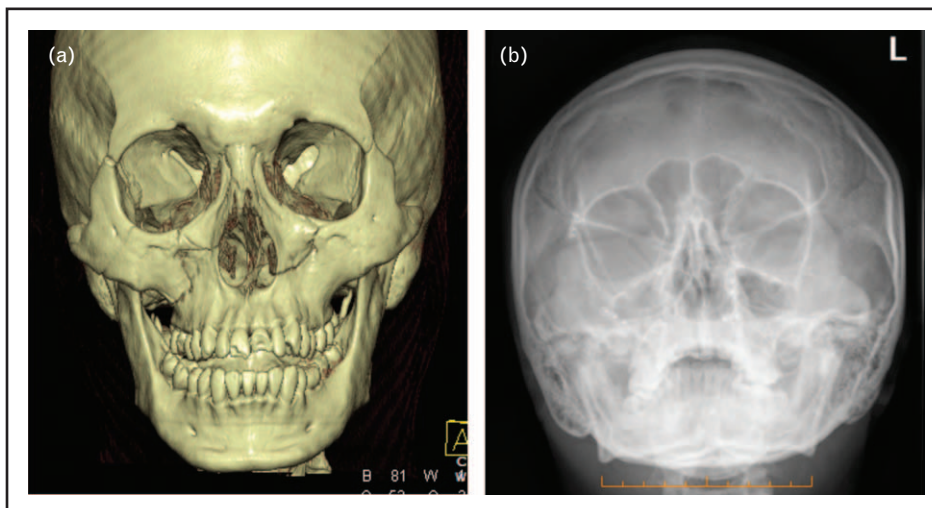


FIGURE 9. (a) Right zygomatico-maxillary complex fracture. (b) Bilateral pterygoid plate dysjunction.

Intraoperative navigation has been available for some time and systems are becoming more user-friendly, less expensive and accessible. The technology can be used to register the patient's anatomy in relation to a preoperative CT scan within a systematic error of 1 mm accuracy [15]. Planning can take place to simulate the contralateral position of a fractured bone, particularly good for zygomas, to give a planned position for reduction. Real-time probe-based navigation can then be used to achieve the desired position and is likely to be useful in such instances as positioning large orbital plates and comminuted zygoma pieces when surgical access may be restricted.

Intraoperative medical and cone beam CT (Fig. 10) will continue to become more commonplace in hospital theatre suites. This gives the unique ability to check fracture reduction and hardware positioning while the patient is still under general anaesthesia and could result in improving accuracy and consistency. There are various applications for facial trauma. The position of an orbital plate can be assessed after placement and once soft tissue traction has been released. Facial symmetry and orbital floor position can be assessed following reduction of a zygoma, and may prevent the further morbidity of a second procedure. Modern

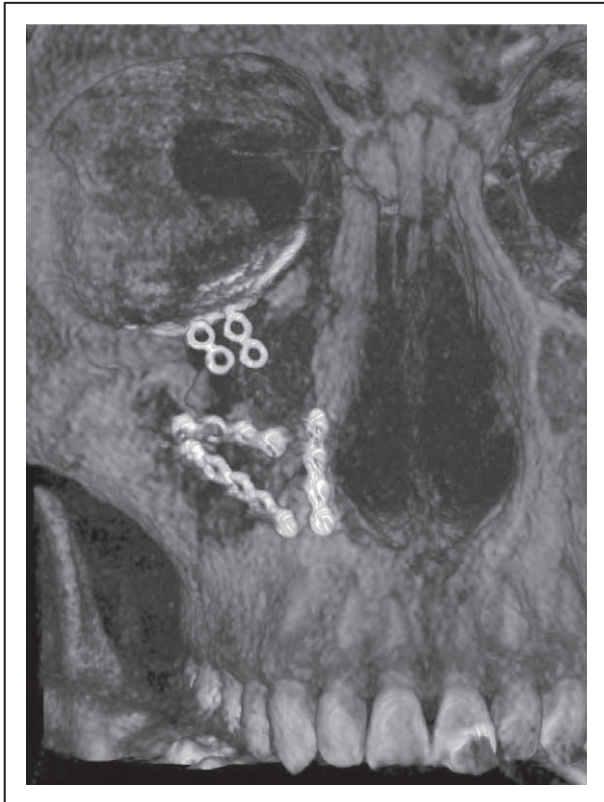


FIGURE 10. Intraoperative cone beam computed tomography imaging.

intraoperative C-arm scanners can be available in theatre and only add 10–15 min on to the case time [16¹¹,17¹¹].

Computer assisted or virtual planning is another area of interest in the field of facial trauma surgery. Planning software such as Proplan CMF can segmentalize the various facial subunits, provide better three-dimensional visualization of the injury and guide the appropriate course of management. 3D printing offers the opportunity to manufacture accurate biomodels from which preformed customized hardware and cutting guides can be fashioned. These techniques all serve to assist the surgeon in more serious traumatic fracture defects.

Finally, approaches to the facial skeleton continue to evolve with refinement of classic approaches and the increasing popularity of endoscopic techniques. With regard to trauma, endoscopic or minimal approaches, particularly to the frontal, orbital or midface region, have yet to be proven to be more useful than the standardized open exposure that allows excellent visualization, anatomical reduction and fixation of fractures. As technology improves with time, perhaps this will change.

Of all these developments, we feel intraoperative CT offers the most practical and immediately useful technology to improve outcomes, and would encourage units to explore this availability.

CONCLUSION

The modern surgical management of midface fractures has continued to evolve, allowing far more accurate repositioning and fixation of the traumatized facial skeleton, along with prevention of deleterious soft tissue postoperative changes. Imaging software improvements have made the understanding of this anatomical area far more precise and treatment has continued to become increasingly customized and refined. The aim will always remain to re-establish the anatomical, functional and aesthetic aspects of the face following midface trauma, whilst limiting posttraumatic and postsurgical deformity to an absolute minimum; advances made in this respect should continue to improve outcomes into the future.

Acknowledgements

The authors thank AOCMF for use of selected diagrams used in the manuscript.

Financial support and sponsorship

None.

Conflicts of interest

There are no conflicts of interest.

Maxillofacial surgery

REFERENCES AND RECOMMENDED READING

Papers of particular interest, published within the annual period of review, have been highlighted as:

- of special interest
- of outstanding interest

1. Perry M. Advanced trauma life support (ATLS) and facial trauma: can one size fit all? Part 1: dilemmas in the management of the multiply injured patient with coexisting facial injuries. *Int J Oral Maxillofac Surg* 2008; 37:209–214.
2. Perry M, Morris C. Advanced trauma life support (ATLS) and facial trauma: can one size fit all? Part 2: ATLS, maxillofacial injuries and airway management dilemmas. *Int J Oral Maxillofac Surg* 2008; 37:309–320.
3. Perry M, O'Hare J, Porter G. Advanced trauma life support (ATLS) and facial trauma: can one size fit all? Part 3: hypovolaemia and facial injuries in the multiply injured patient. *Int J Oral Maxillofac Surg* 2008; 37:405–414.
4. Perry M, Moutray T. Advanced trauma life support (ATLS) and facial trauma: can one size fit all? Part 4: 'can the patient see?' Timely diagnosis, dilemmas and pitfalls in the multiply injured, poorly responsive/unresponsive patient. *Int J Oral Maxillofac Surg* 2008; 37:505–514.
5. Le Fort R. Étude expérimentale sur les fractures de la machoire supérieure. *Rev Chir Paris* 1901; 23:208–227; 360–79, 479–507.
6. Hopper RA, Salemy S, Sze RW. Diagnosis of midface fractures with CT: what the surgeon needs to know *Radiographics* 2006; 26:783–793. AQ7
7. Kaur J, Chopra R. Three dimensional CT reconstruction for the evaluation and surgical planning of mid face fractures: a 100 case study. *J Maxillofac Oral Surg* 2010; 9:323–328.
8. Marciani RD. Management of midface fractures: fifty years later. *J Oral Maxillofac Surg* 1993; 51:960–968.
9. Donat TL, Endress C, Mathog RH. Facial fracture classification according to skeletal support mechanisms. *Arch Otolaryngol Head Neck Surg* 1998; 124:1306–1314.
10. Cornelius CP, Audigé L, Kunz C, *et al.* The comprehensive AOCMF classification system: midface fractures – level 3 tutorial. *Craniomaxillofac Trauma Reconstr* 2014; 7 (Suppl 1):S068–S091.
11. Manson PN, Clark N, Robertson B, *et al.* Subunit principles in midface fractures: the importance of sagittal buttresses, soft-tissue reductions, and sequencing treatment of segmental fractures. *Plast Reconstr Surg* 1999; 103:1287–1306. AQ8
12. Dutton GN, al-Qurainy I, Stassen LF, *et al.* Ophthalmic consequences of midfacial trauma. *Eye (Lond)* 1992; 6:86–89.
13. Gruss JS, Mackinnon SE. Complex maxillary fractures: role of buttress reconstruction and immediate bone grafts. *Plast Reconstr Surg* 1986; 78:9–22.
14. Carron MA, Zuliani G, Pereira L, *et al.* Stability of midface fracture repair using absorbable plate and screw system pilot holes drilled and pin placement at angles other than 90°. *JAMA Facial Plast Surg* 2014; 16:42–48.
15. Kim JW, Wu J, Shen SG, *et al.* Interdisciplinary surgical management of multiple facial fractures with image-guided navigation. *J Oral Maxillofac Surg* 2015; 73:1767–1777.
16. Morrison CS, Taylor HO, Collins S, *et al.* Use of intraoperative computed tomography in complex craniofacial trauma: an example of on-table change in management. *Craniomaxillofac Trauma Reconstr* 2014; 7:298–301.
17. van Hout WM, Van Cann EM, Muradin MS, *et al.* Intraoperative imaging for the repair of zygomaticomaxillary complex fractures: a comprehensive review of the literature. *J Craniomaxillofac Surg* 2014; 42:1918–1923.

MOO

Manuscript No. 240403

**Current Opinion in Otolaryngology & Head and
Neck Surgery**
Typeset by Thomson Digital
for Wolters Kluwer

Dear Author,

During the preparation of your manuscript for typesetting, some queries have arisen. These are listed below. Please check your typeset proof carefully and mark any corrections in the margin as neatly as possible or compile them as a separate list. This form should then be returned with your marked proof/list of corrections to the Production Editor.

QUERIES: to be answered by AUTHOR/EDITOR?

QUERY NO.	QUERY DETAILS	RESPONSE
<AQ1>	Please confirm whether surnames/family names (red) have been identified correctly in the author byline.	
<AQ2>	Please check the affiliation and correspondence for correctness.	
<AQ3>	As per style, only one e-mail has been retained. Please check.	
<AQ4>	As per style of the journal abstract should be structured with headings 'Purpose of review', 'Recent findings' and 'Summary'. This has been done. Please check.	
<AQ5>	Please define acronyms ATLS, AOCMF, MMF, if possible.	
<AQ6>	Please check the heading levels for correctness.	
<AQ7>	Please check the journal title, volume number, year of publication and page range in Ref. [6].	
<AQ8>	As per journal style, all annotated reference numbers must have bullets, and all reference numbers with bullets must have annotations. In the case of Refs. [10, 16, 17], please provide annotations.	
<AQ9>	We have suggested the captions placements for the figures introduced. Kindly check if they have back set correctly.	